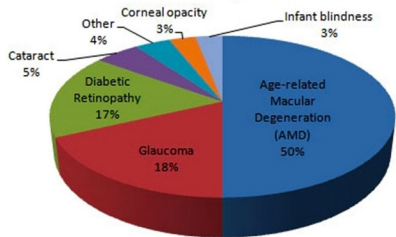


Unraveling AMD: A Clinical Overview and Therapeutic Strategies

Eljot Cherkas, MD
Casey Eye Institute Resident
2024 OAO Ophthalmic Tech Conference

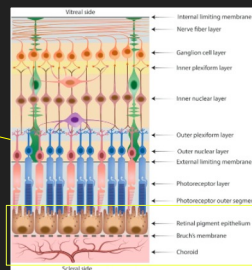
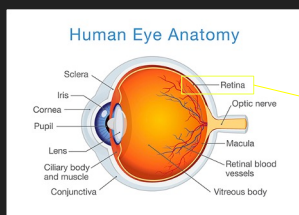
1

Causes of blindness in the most developed countries



2

Relevant anatomy



3

Relevant anatomy OCT

Retinal Layers	
Abbr.	Name
ILM	Internal Limiting Membrane
RNFL	Retinal Nerve Fibre Layer
GCL	Ganglion Cell Layer
IPL	Inner Plexiform Layer
INL	Inner Nuclear Layer
OPL	Outer Plexiform Layer
ONL	Outer Nuclear Layer
ELM	External Limiting Membrane
PR	Photoreceptor Layers
RPE	Retinal Pigment Epithelium
BM	Bruch's Membrane
CC	Choriocapillaris
CS	Choroidal Stroma

4

Overview

- A medical condition which may result in blurred or no vision in the center of the visual field.
- Leading cause of vision loss
- 2 main clinical stages:
 - Early/intermediate non-exudative stage (dry AMD)
 - Late stage (advanced AMD)
 - Non-neovascular (central geographic atrophy) - 90%
 - Neovascular (macular/choroidal neovascularization) - 10%

5

6

Pathophysiology

- Not entirely known/understood! Some theories:
 - Drusen Formation**
 - Basal Laminal Drusen, Basal Linear Drusen
 - Small, intermediate, large
 - Hard, soft, confluent
 - RPE Dysfunction**
 - Focal vs geographic atrophy
 - Serous detachments of the RPE
 - Choroidal Neovascularization (CNV)**
 - Type 1
 - Type 2
 - Type 3
 - Inflammatory Responses
 - Photoreceptor Cell Death

7

Signs and Symptoms

- Early forms may be asymptomatic
- Decreased vision**
 - Dry: gradual vision loss
 - Wet: rapid vision loss
- Blurred vision**
- Distorted vision (**metamorphopsia**)

8


Non-modifiable risk factors

- Non-modifiable**
 - Age
 - Female sex
 - Race (highest in White, lowest in African-American)
 - Family history
 - Hyperopia
 - Light irides

9

Non-modifiable risk factors

- **Modifiable**
 - Smoking
 - Low micronutrient intake
 - Hypertension
 - Hypercholesterolemia
 - Cardiovascular disease



10

Progression

Number of Risk Factor Points	5-Year Risk, %	10-Year Risk, %
0	0.5	1
1	3	7
2	12	22
3	25	50
4	50	67

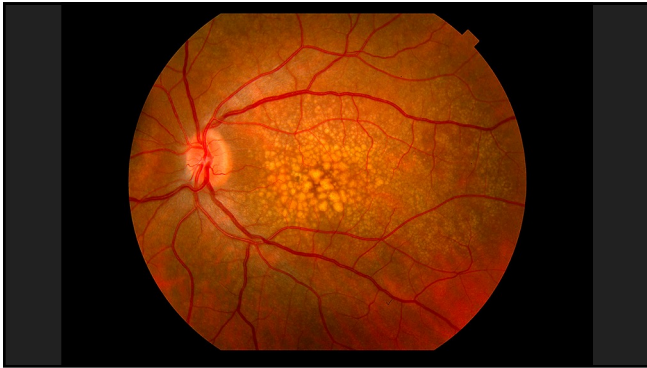
AMD=age-related macular degeneration.
^a Risks are based on the number of Age-Related Eye Disease Study (AREDS) risk factors (see text).

11

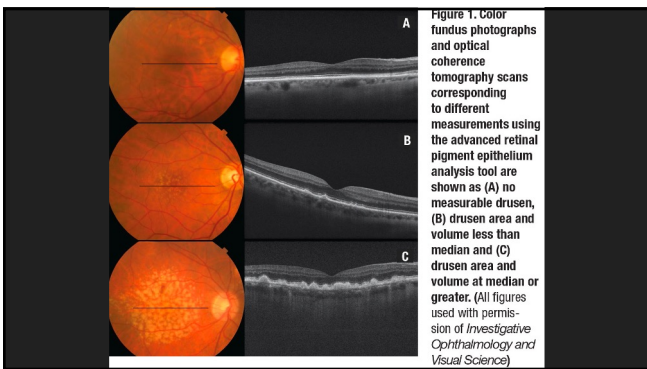Imaging Modalities

- Optical Coherence Tomography (OCT)
- OCT Angiography
- Retinal Fundus Photography
- Autofluorescence Imaging
- Scanning Laser Ophthalmoscopy

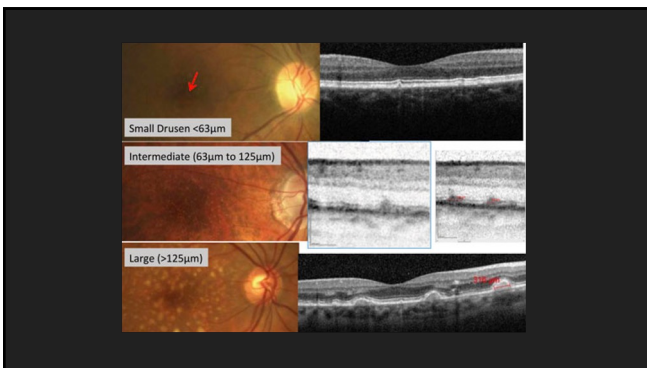
12



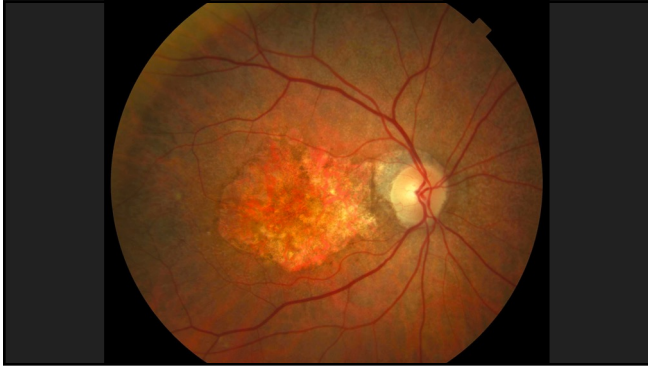13



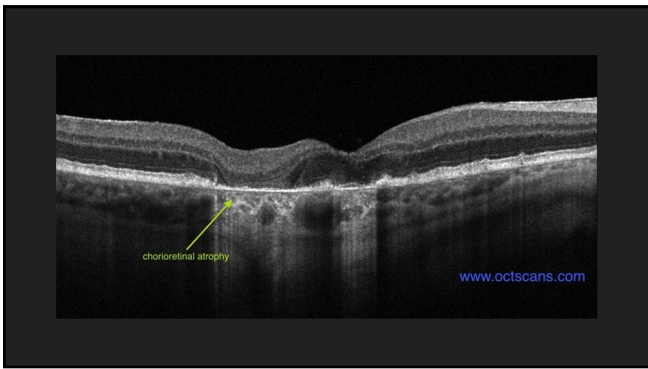
14



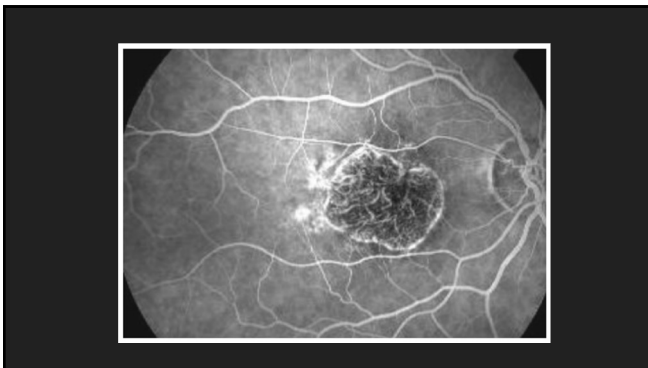
15



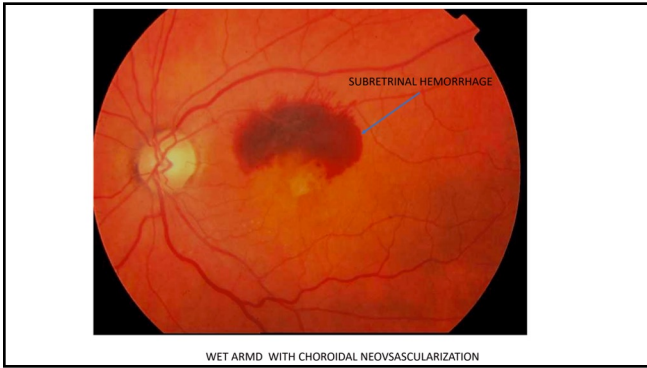
16

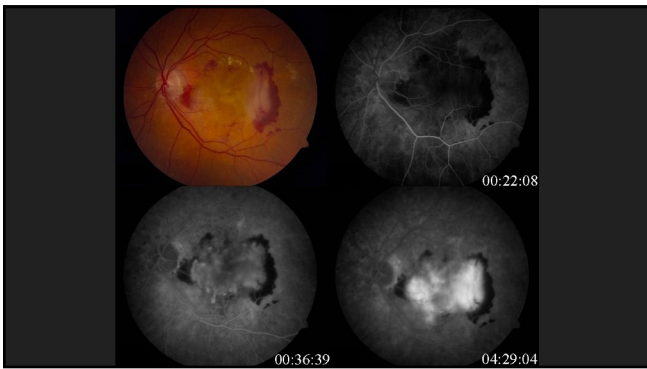


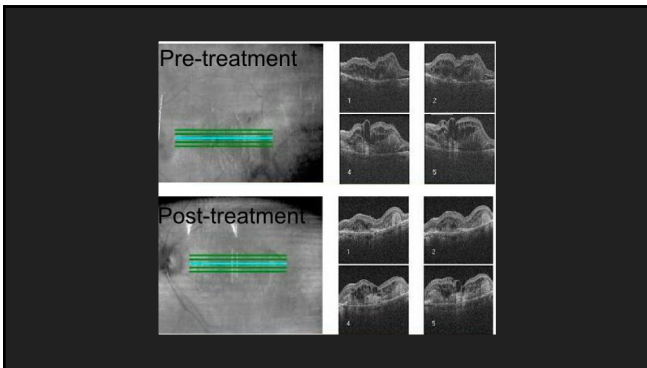
17



18








Management

- **Non-neovascular AMD:**
 - Eliminate modifiable risk factors
 - AREDS vs AREDS2:
 - Vitamin C
 - Vitamin E
 - Beta-carotene vs Zeaxanthin + Lutein
 - Copper Oxide
 - Zinc Oxide
 - Amsler Grid
- **Neovascular AMD:**
 - Laser photocoagulation (rare)
 - Photodynamic therapy
 - Anti-VEGF injections
 - Lucentis (Ranibizumab)
 - Eylea (Aflibercept)
 - Avastin (Bevacizumab)
 - Beovu (Brolucizumab)
 - Combination therapies

22

Thank you!



23