




Emergencies
Joe Simonett, MD
Vitreoretinal Surgery
jmsimonett@gmail.com



1

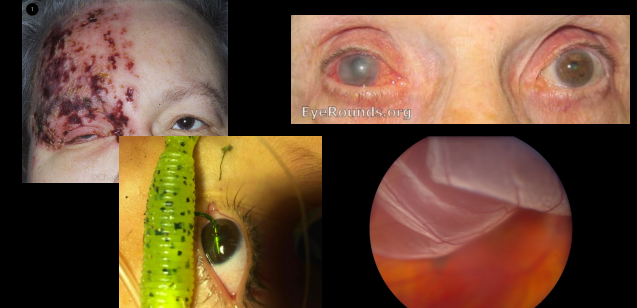


Emergencies
Joe Simonett, MD
Vitreoretinal Surgery
jmsimonett@gmail.com



2

Ocular Emergencies



3

Ocular Emergencies

Patients usually don't tell us the diagnosis...

4

Ocular Emergencies

Patients usually don't tell us the diagnosis...

And sometimes they don't tell us its an emergency!

5

THE NEW YORK TIMES BESTSELLER

THINKING, FAST AND SLOW

DANIEL KAHNEMAN

WINNER OF THE NOBEL PRIZE IN ECONOMICS

SYSTEM 1
Intuition & instinct

95%

Unconscious
Fast
Associative
Automatic pilot

SYSTEM 2
Rational thinking

5%

Takes effort
Slow
Logical
Lazy
Indecisive

6

The image shows the cover of the book "Thinking, Fast and Slow" by Daniel Kahneman. To the right is a diagram illustrating the two systems of thought:

- Working through an overlooked clinic**: **SYSTEM 1** Intuition & instinct. It is associated with 95% of thought and is unconscious, fast, associative, and automatic (like a pilot).
- Working up a difficult, confusing case**: **SYSTEM 2** Rational thinking. It is associated with 5% of thought and takes effort, is slow, logical, and laborious (like a doctor).

7

Acute, painless vision loss

tedmontrosmv

8


Vision loss case 1

79 year old man with HTN and Afib presents with vision loss

"I can't see out of my left eye!
Cars keep coming out of nowhere on my left side"

9

Vision loss case 1




Check vital signs:

79 year old man with HTN and Afib presents with vision loss

"I can't see out of my left eye!
Cars keep coming out of nowhere on my left side"

10

Vision loss case 1



Check vital signs:


1. Vision

79 year old man with HTN and Afib presents with vision loss

"I can't see out of my left eye!
Cars keep coming out of nowhere on my left side"

11

Vision loss case 1



Check vital signs:


1. Vision - 20/20 OU

79 year old man with HTN and Afib presents with vision loss

"I can't see out of my left eye!
Cars keep coming out of nowhere on my left side"


12


Pupils – looking for an afferent pupillary defect




79 year old man with HTN and Afib presents with vision loss

“I can’t see out of my left eye!
Cars keep coming out of nowhere on my left side”

No Light 


Normal Response to Light 

Positive RAPD of Right Eye 

Stanford Medicine 2019


13

Pupils – looking for an afferent pupillary defect




79 year old man with HTN and Afib presents with vision loss

“I can’t see out of my left eye!
Cars keep coming out of nowhere on my left side”



14

Vision loss case 1



79 year old man with HTN and Afib presents with vision loss


“I can’t see out of my left eye!
Cars keep coming out of nowhere on my left side”

Check vital signs:

1. Vision – 20/20 OU
2. Pupils – No rAPD

15

Vision loss case 1



79 year old man with HTN and Afib presents with vision loss


"I can't see out of my left eye!
Cars keep coming out of nowhere on my left side"

Check vital signs:
1. Vision – 20/20 OU
2. Pupils – **No rAPD**

In a busy clinic, it is tempting to only work up the left eye...

16

Vision loss case 1



79 year old man with HTN and Afib presents with vision loss

"I can't see out of my left eye!
Cars keep coming out of nowhere on my left side"

Check vital signs:
1. Vision – 20/20 OU
2. Pupils – **No rAPD**

In a busy clinic, it is tempting to only work up the left eye...

But lets think slow.

17


Visual Fields




79 year old man with HTN and Afib presents with vision loss

"I can't see out of my left eye!
Cars keep coming out of nowhere on my left side"

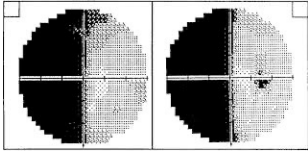
18




79 year old man with HTN and Afib presents with vision loss

"I can't see out of my left eye!
Cars keep coming out of nowhere on my left side"

Visual Fields



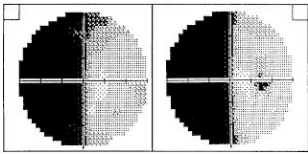
19



79 year old man with HTN and Afib presents with vision loss


"I can't see out of my left eye!
Cars keep coming out of nowhere on my left side"

Visual Fields



Left homonymous hemianopsia –
caused by stroke in visual cortex of
brain

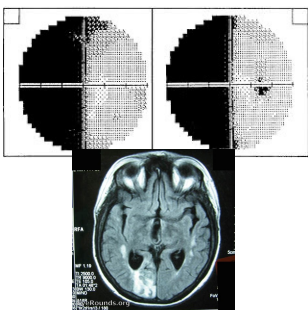
20



79 year old man with HTN and Afib presents with vision loss


"I can't see out of my left eye!
Cars keep coming out of nowhere on my left side"

Visual Fields



21

Vision loss case 2




81 year old woman with Afib presents with sudden onset vision loss

"I can't see out of my right eye!"

22

Vision loss case 2



81 year old woman with Afib presents with sudden onset vision loss


"I can't see out of my right eye!"

Check vital signs:

1. Vision – CF OD, 20/20 OS
2. Pupils – right rAPD
3. Visual field

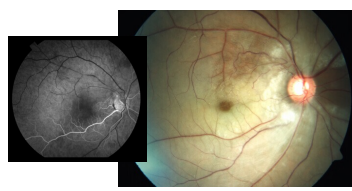
23

Vision loss case 2



81 year old woman with Afib presents with sudden onset vision loss

"I can't see out of my right eye!"




Retinal artery occlusion

Check vital signs:

1. Vision – CF OD, 20/20 OS
2. Pupils – right rAPD
3. Visual field

24


Vision loss case 2



Emergency referral to stroke center for brain and vascular imaging and neurology consult – fast intervention can prevent stroke

81 year old woman with Afib presents with sudden onset vision loss

“I can’t see out of my right eye!”




Retinal artery occlusion

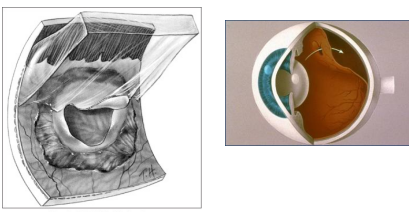
25

Vision loss case 3

Retinal tears and detachments



85 year old man with new flashes or floaters





Copyright 2006 by Elsevier, Inc.

26

Vision loss case 3

Phone triage is hard


85 year old man with new flashes or floaters

Highest risk of tear or detachment

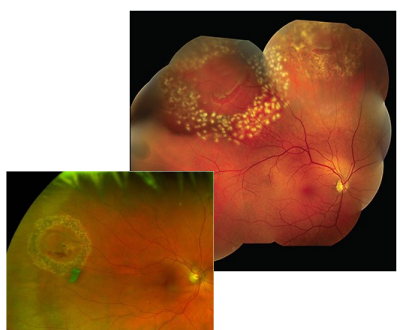
1. Is it 1 eye or both? (higher risk of unilateral)
2. Did symptoms start within last 3 days?
3. Do you have a non-moving shadow in the side of your vision?
4. When you were young, did you need glasses to drive?
5. Have you had a prior retinal tear or had retinal surgery?

27

Vision loss case 3




85 year old man with new flashes or floaters

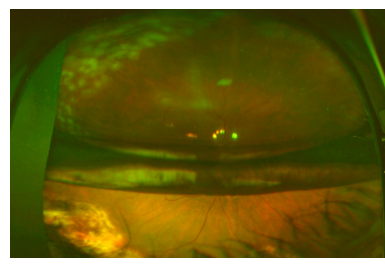


28


Vision loss case 3



85 year old man with new flashes or floaters




29





Acute, painful vision loss

30



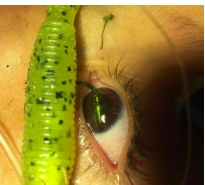

8 year old went fishing with his dad...

31



8 year old went fishing with his dad...

32



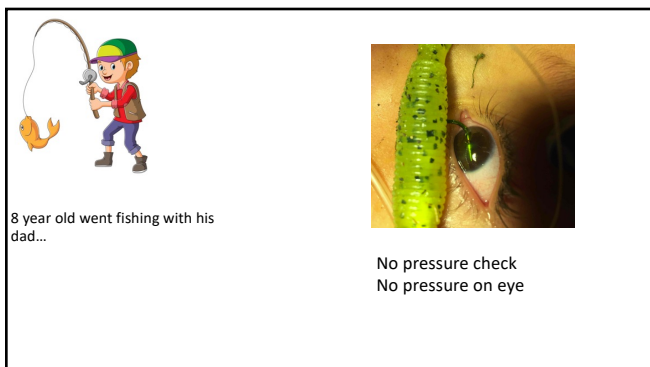
8 year old went fishing with his dad...

Don't pull it out!

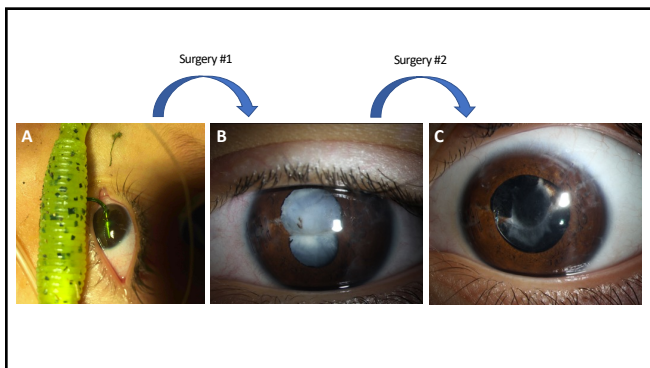
33




34



35


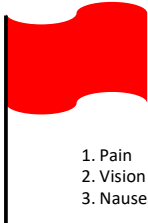


36



62 year old patient with who had cataract surgery 4 days ago calls with eye pain and vision loss.


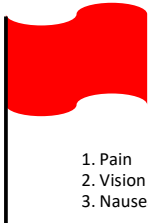
37

62 year old patient with who had cataract surgery 4 days ago calls with eye pain and vision loss.

1. Pain
2. Vision loss
3. Nausea/vomiting

38





62 year old patient with who had cataract surgery 4 days ago calls with eye pain and vision loss.

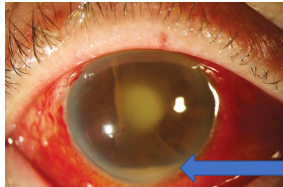
1. Pain
2. Vision loss
3. Nausea/vomiting

When in doubt, bring in post-ops

39




62 year old patient with who had cataract surgery 4 days ago calls with eye pain and vision loss.

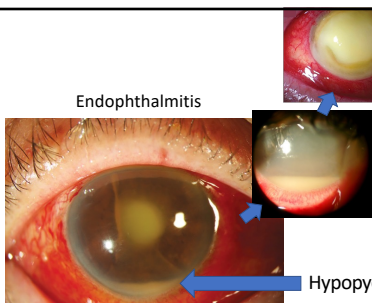


Hypopyon

40



62 year old patient with who had cataract surgery 4 days ago calls with eye pain and vision loss.

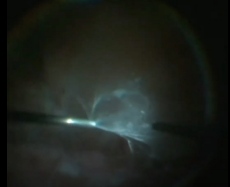
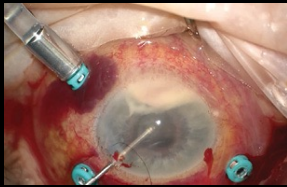


Endophthalmitis


Hypopyon

41

Needs urgent intravitreal antibiotics +/- vitrectomy




42



68 year old woman with 12 hours of eye pain, seeing halos, and nausea and vomiting

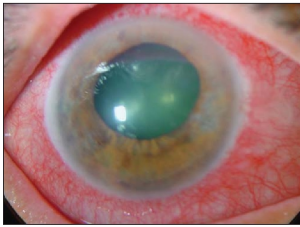

43



68 year old woman with 12 hours of eye pain, seeing halos, and nausea and vomiting

Check vital signs:
1. Vision – CF OD, 20/20 OS
2. Pupils – ???
3. IOP - 55


44



68 year old woman with 12 hours of eye pain, seeing halos, and nausea and vomiting

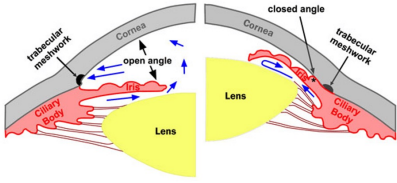
Figure 4. 2024

45



68 year old woman with 12 hours of eye pain, seeing halos, and nausea and vomiting


Angle closure glaucoma



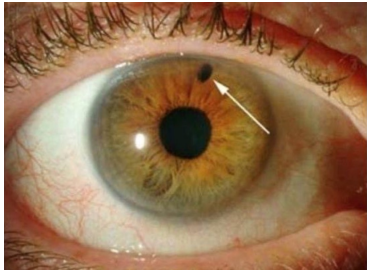
Labels in diagram: Trabecular meshwork, Cornea, open angle, Ciliary Body, Lens, closed angle, Cornea, trabecular meshwork, Ciliary Body, Lens.

<https://melbournecentre.com.au/glaucoma/closed-angle-glaucoma/>

46



68 year old woman with 12 hours of eye pain, seeing halos, and nausea and vomiting



47

Acute onset double vision in an Adult (diplopia)



48

New onset double vision in an Adult (diplopia)

Monocular

No emergency

- Astigmatism
- Cataract
- Epiretinal membrane

49

New onset double vision in an Adult (diplopia)

Monocular

No emergency

- Astigmatism
- Cataract
- Epiretinal membrane

Binocular

Possible emergency

- The two eyes are not lining up
- Eye muscle problem (thyroid eye disease, orbital cellulitis, trauma)
- Cranial nerve 3, 4 or 6 problem
 - Compression from tumor, aneurysm, or high ICP
 - Ischemia (HTN, DM, Giant cell arteritis)
- Brain problem (CVA, myasthenia gravis, global dysfunction/encephalopathy)

50

New onset double vision in an Adult (diplopia)

Binocular

Extraocular muscle entrapment

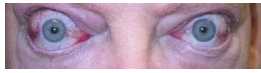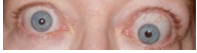Possible emergency

- The two eyes are not lining up
- Eye muscle problem (thyroid eye disease, orbital cellulitis, trauma)
- Cranial nerve 3, 4 or 6 problem
 - Compression from tumor, aneurysm, or high ICP
 - Ischemia (HTN, DM, Giant cell arteritis)
- Brain problem (CVA, myasthenia gravis, global dysfunction/encephalopathy)

51

New onset double vision in an Adult (diplopia)

Thyroid eye disease



Binocular

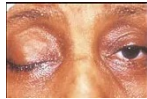Possible emergency

- The two eyes are not lining up
- Eye muscle problem (thyroid eye disease, orbital cellulitis, trauma)
- Cranial nerve 3, 4 or 6 problem
 - Compression from tumor, aneurysm, or high ICP
 - Ischemia (HTN, DM, Giant cell arteritis)
- Brain problem (CVA, myasthenia gravis, global dysfunction/encephalopathy)

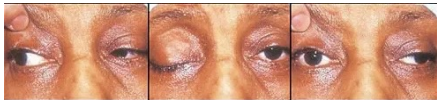52

Double vision case #1

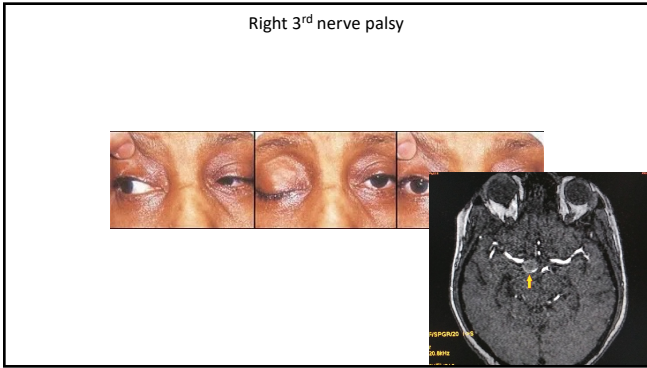
89 yo presents with double vision and a headache
"I think I am better, I'm not having double vision anymore!"



53



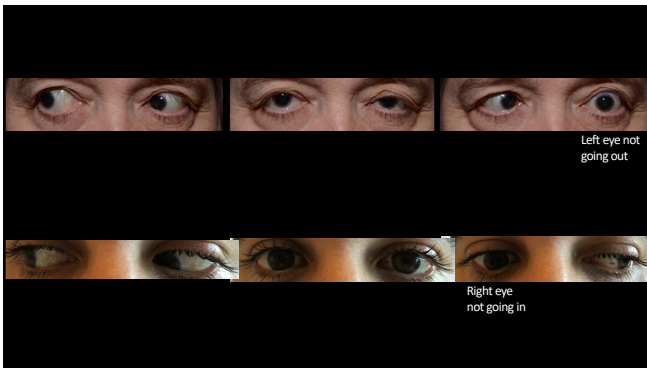54



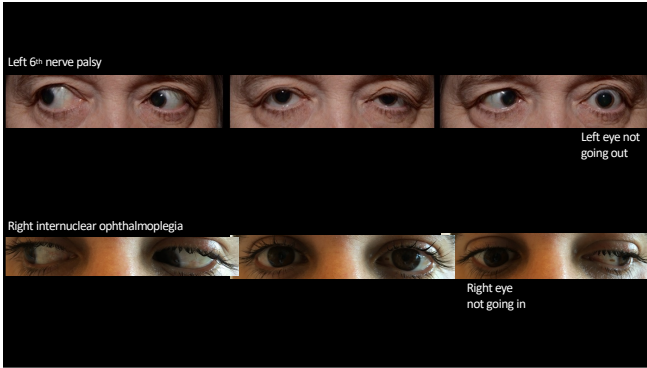55



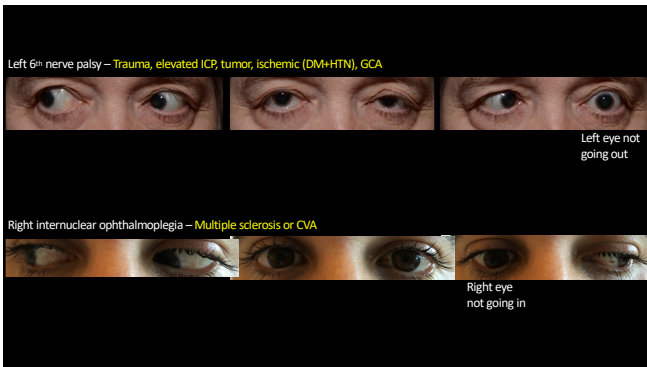
56



57



58




59

Ocular Emergencies

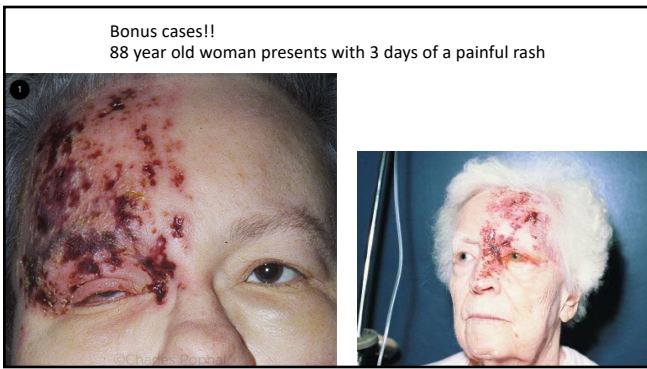1. Acute, *painless* vision loss
2. Acute, *painful* vision loss
3. Acute onset, binocular double vision

Don't forget to think slow

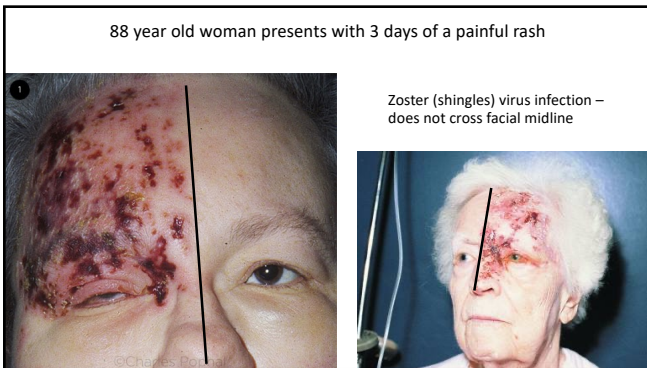60



61

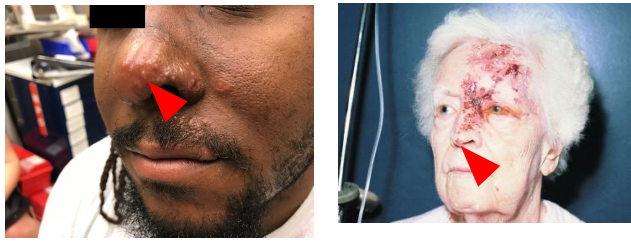

62



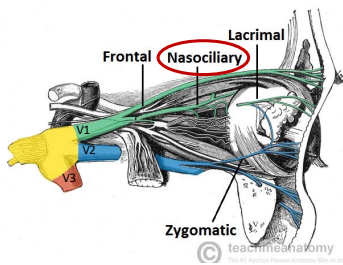
63

Hutchinson's Sign



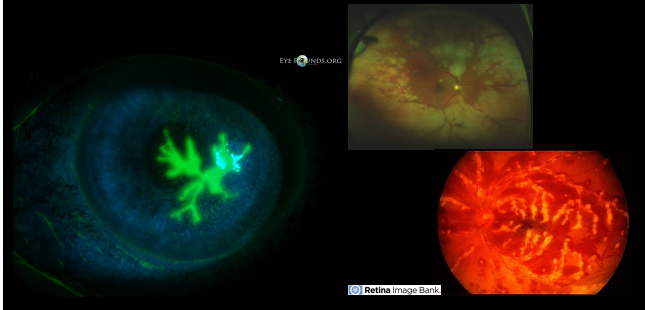64

Hutchinson's Sign

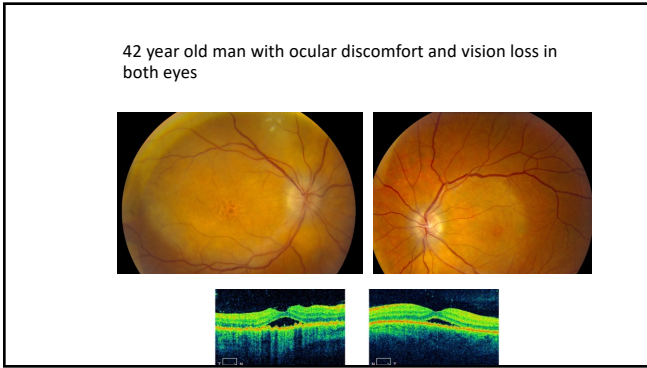


65

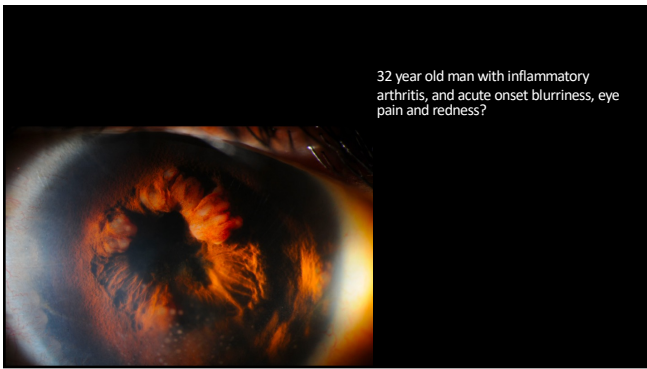Ocular manifestations of VZV and HSV



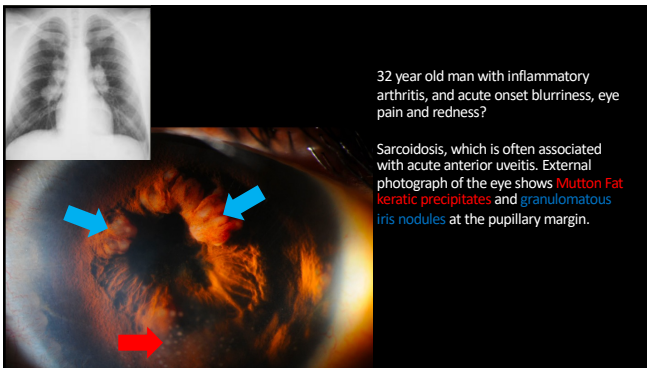66



67



68



69
