




Emergencies
Joe Simonett, MD
Vitreoretinal Surgery
jmsimonett@gmail.com



1

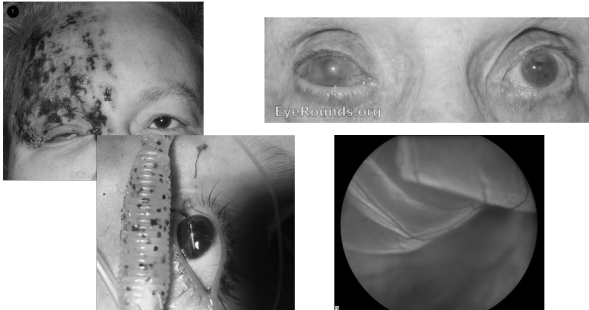


Emergencies
Joe Simonett, MD
Vitreoretinal Surgery
jmsimonett@gmail.com



2

Ocular Emergencies



3

Ocular Emergencies

Patients usually don't tell us the diagnosis...

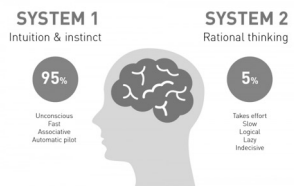

4

Ocular Emergencies

Patients usually don't tell us the diagnosis...

And sometimes they don't tell us its an emergency!

5



6

Working through an overbooked clinic

Working up a difficult, confusing case

SYSTEM 1
Intuition & instinct

SYSTEM 2
Rational thinking

95%

Unconscious
Fast
Associative
Automatic pilot

5%

Takes effort
Slow
Logical
Lazy
Indecisive

7

Acute, *painless* vision loss

tedmontmery

8


Vision loss case 1

79 year old man with HTN and Afib presents with vision loss

"I can't see out of my left eye!
Cars keep coming out of nowhere on my left side"

9

Vision loss case 1




79 year old man with HTN and Afib presents with vision loss

“I can’t see out of my left eye!
Cars keep coming out of nowhere on my left side”

Check vital signs:

10

Vision loss case 1




79 year old man with HTN and Afib presents with vision loss

“I can’t see out of my left eye!
Cars keep coming out of nowhere on my left side”

Check vital signs:
1. Vision

11

Vision loss case 1




79 year old man with HTN and Afib presents with vision loss

“I can’t see out of my left eye!
Cars keep coming out of nowhere on my left side”

Check vital signs:
1. Vision – 20/20 OU


12


Pupils – looking for an afferent pupillary defect




79 year old man with HTN and Afib presents with vision loss

“I can’t see out of my left eye!
Cars keep coming out of nowhere on my left side”


No Light 

Normal Response to Light 

Positive RAPD of Right Eye 


13

Pupils – looking for an afferent pupillary defect




79 year old man with HTN and Afib presents with vision loss

“I can’t see out of my left eye!
Cars keep coming out of nowhere on my left side”



14

Vision loss case 1




79 year old man with HTN and Afib presents with vision loss

“I can’t see out of my left eye!
Cars keep coming out of nowhere on my left side”

Check vital signs:
1. Vision – 20/20 OU
2. Pupils – No rAPD

15

Vision loss case 1



79 year old man with HTN and Afib presents with vision loss


“I can’t see out of my left eye!
Cars keep coming out of nowhere on my left side”

Check vital signs:
1. Vision – 20/20 OU
2. Pupils – No rAPD

In a busy clinic, it is tempting to only work up the left eye...

16

Vision loss case 1



79 year old man with HTN and Afib presents with vision loss


“I can’t see out of my left eye!
Cars keep coming out of nowhere on my left side”

Check vital signs:
1. Vision – 20/20 OU
2. Pupils – No rAPD

In a busy clinic, it is tempting to only work up the left eye...

But lets think slow.


17



79 year old man with HTN and Afib presents with vision loss

“I can’t see out of my left eye!
Cars keep coming out of nowhere on my left side”

Visual Fields

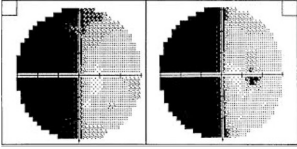


18

79 year old man with HTN and Afib presents with vision loss

"I can't see out of my left eye!
Cars keep coming out of nowhere on my left side"

Visual Fields




19

79 year old man with HTN and Afib presents with vision loss

"I can't see out of my left eye!
Cars keep coming out of nowhere on my left side"

Visual Fields



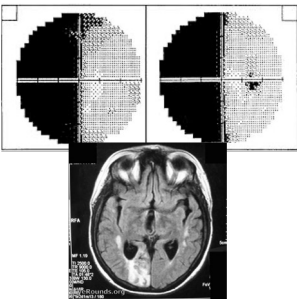
Left homonymous hemianopia –
caused by stroke in visual cortex of
brain

20

79 year old man with HTN and Afib presents with vision loss


"I can't see out of my left eye!
Cars keep coming out of nowhere on my left side"

Visual Fields



21

Vision loss case 2




81 year old woman with Afib presents with sudden onset vision loss

"I can't see out of my right eye!"

22

Vision loss case 2



81 year old woman with Afib presents with sudden onset vision loss

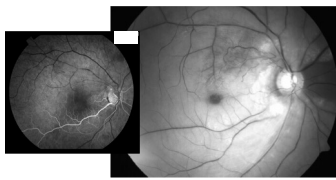

"I can't see out of my right eye!"

Check vital signs:

1. Vision – CF OD, 20/20 OS
2. Pupils – right rAPD
3. Visual field

23

Vision loss case 2



81 year old woman with Afib presents with sudden onset vision loss

"I can't see out of my right eye!"


Retinal artery occlusion

Check vital signs:

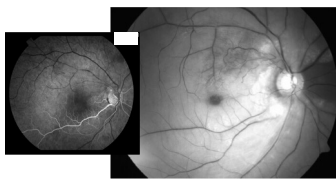
1. Vision – CF OD, 20/20 OS
2. Pupils – right rAPD
3. Visual field

24

Vision loss case 2



Emergency referral to stroke center for brain and vascular imaging and neurology consult – fast intervention can prevent stroke



81 year old woman with Afib presents with sudden onset vision loss


“I can’t see out of my right eye!”

Retinal artery occlusion

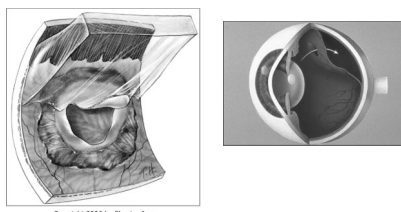
25

Vision loss case 3

Retinal tears and detachments



85 year old man with new flashes or floaters




Copyright 2006 by Elsevier, Inc.

26

Vision loss case 3

Phone triage is hard



85 year old man with new flashes or floaters

Ophthalmology Retina AMERICAN ACADEMY OF OPHTHALMOLOGY

A Telephone Triage System for Patients Calling with Symptoms of a Posterior Vitreous Detachment

Daniel A. Balkov, MD, PhD • Yunshu Zhou, MS • Jason M.L. Miller, MD, PhD


Published: January 09, 2023 • DOI: <https://doi.org/10.1016/j.oret.2023.01.003> • Check for updates

Highest risk of tear or detachment

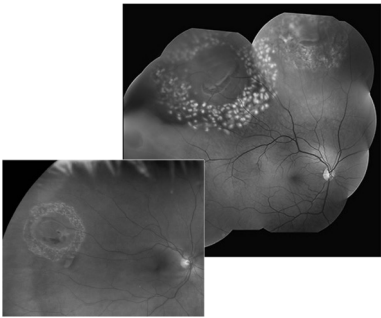
1. Is it 1 eye or both? (higher risk of unilateral)
2. Did symptoms start within last 3 days?
3. Do you have a non-moving shadow in the side of your vision?
4. When you were young, did you need glasses to drive?
5. Have you had a prior retinal tear or had retinal surgery?

27

Vision loss case 3




85 year old man with new flashes or floaters

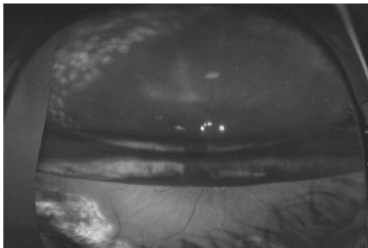


28

Vision loss case 3

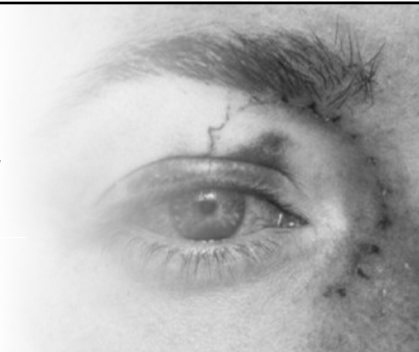


85 year old man with new flashes or floaters




29

Acute, *painful* vision loss

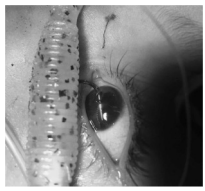



30



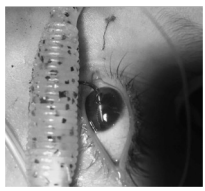

8 year old went fishing with his dad...

31



8 year old went fishing with his dad...

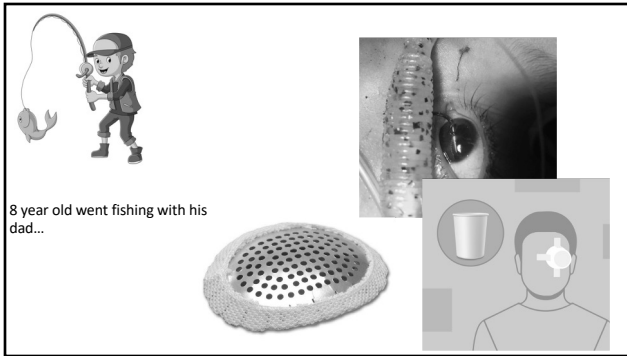
32



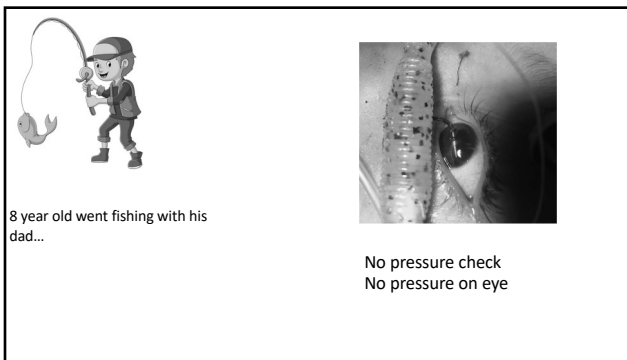
8 year old went fishing with his dad...

Don't pull it out!

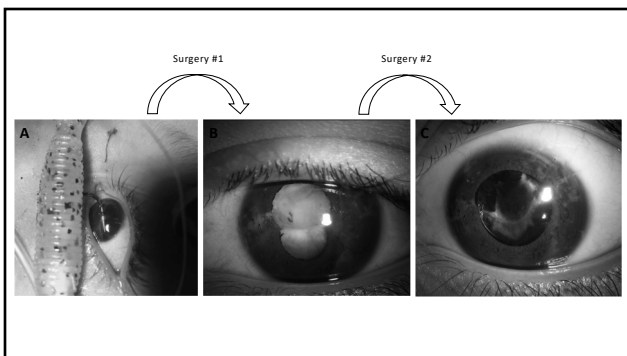
33




34



35




36



62 year old patient with who had cataract surgery 4 days ago calls with eye pain and vision loss.


37



62 year old patient with who had cataract surgery 4 days ago calls with eye pain and vision loss.

- 1. Pain
- 2. Vision loss
- 3. Nausea/vomiting

38




62 year old patient with who had cataract surgery 4 days ago calls with eye pain and vision loss.

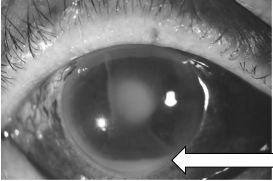
- 1. Pain
- 2. Vision loss
- 3. Nausea/vomiting

When in doubt, bring in post-ops

39




62 year old patient with who had cataract surgery 4 days ago calls with eye pain and vision loss.

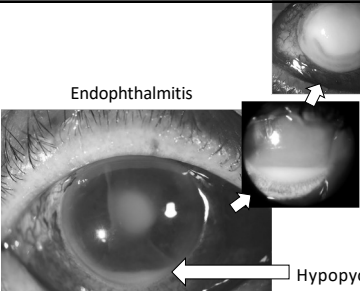


Hypopyon

40



62 year old patient with who had cataract surgery 4 days ago calls with eye pain and vision loss.


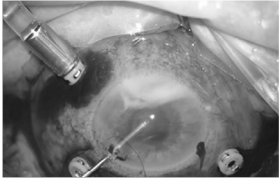


Endophthalmitis


Hypopyon

41

Needs urgent intravitreal antibiotics +/- vitrectomy




42



68 year old woman with 12 hours of eye pain, seeing halos, and nausea and vomiting

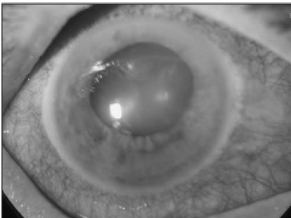

43



68 year old woman with 12 hours of eye pain, seeing halos, and nausea and vomiting


Check vital signs:
1. Vision – CF OD, 20/20 OS
2. Pupils – ???
3. IOP - 55

44



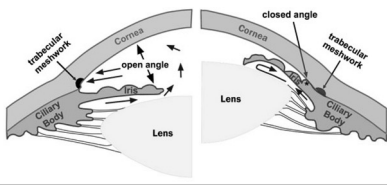
68 year old woman with 12 hours of eye pain, seeing halos, and nausea and vomiting

45




68 year old woman with 12 hours of eye pain, seeing halos, and nausea and vomiting

Angle closure glaucoma

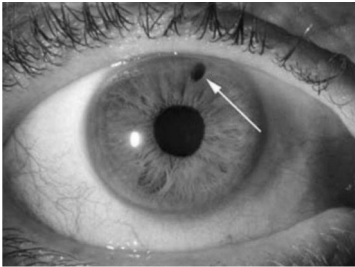


<http://netlibrary.com.au/glaucoma/closed-angle-glaucoma/>

46




68 year old woman with 12 hours of eye pain, seeing halos, and nausea and vomiting



47

Acute onset double vision in an Adult (diplopia)



48

New onset double vision in an Adult (diplopia)

Monocular

No emergency

- Astigmatism
- Cataract
- Epi-retinal membrane

49

New onset double vision in an Adult (diplopia)

Monocular

No emergency

- Astigmatism
- Cataract
- Epi-retinal membrane

Binocular

Possible emergency

- The two eyes are not lining up
- Eye muscle problem (thyroid eye disease, orbital cellulitis, trauma)
- Cranial nerve 3, 4 or 6 problem
 - Compression from tumor, aneurysm, or high ICP
 - Ischemia (HTN, DM, Giant cell arteritis)
- Brain problem (CVA, myasthenia gravis, global dysfunction/encephalopathy)

50

New onset double vision in an Adult (diplopia)

Binocular

Extraocular muscle entrapment


Possible emergency

- The two eyes are not lining up
- Eye muscle problem (thyroid eye disease, orbital cellulitis, trauma)
- Cranial nerve 3, 4 or 6 problem
 - Compression from tumor, aneurysm, or high ICP
 - Ischemia (HTN, DM, Giant cell arteritis)
- Brain problem (CVA, myasthenia gravis, global dysfunction/encephalopathy)

51

New onset double vision in an Adult (diplopia)

Thyroid eye disease



Binocular


Possible emergency

- The two eyes are not lining up
- Eye muscle problem (thyroid eye disease, orbital cellulitis, trauma)
- Cranial nerve 3, 4 or 6 problem
 - Compression from tumor, aneurysm, or high ICP
 - Ischemia (HTN, DM, Giant cell arteritis)
- Brain problem (CVA, myasthenia gravis, global dysfunction/encephalopathy)


52

Double vision case #1

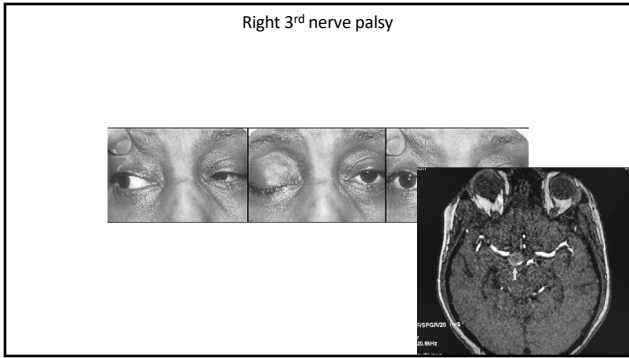
89 yo presents with double vision and a headache
"I think I am better, I'm not having double vision anymore!"



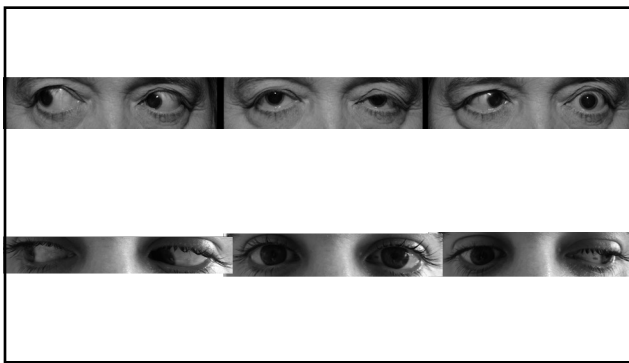
53



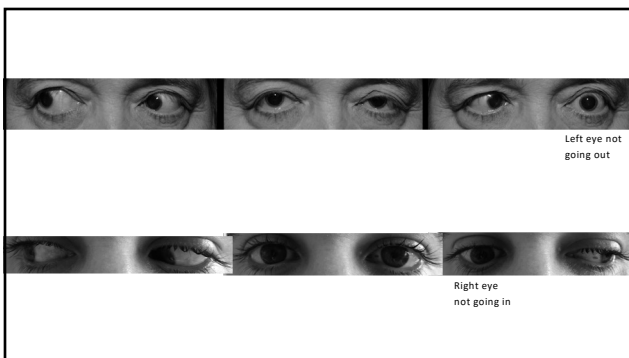
54



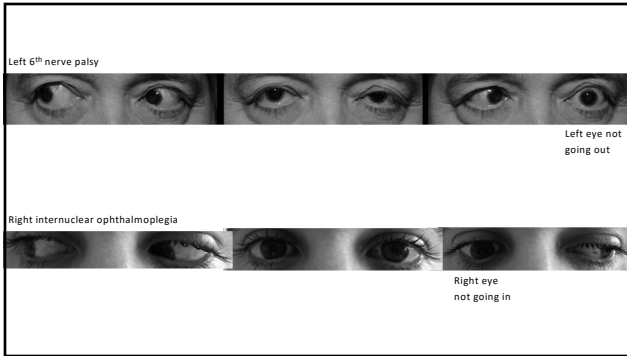
55



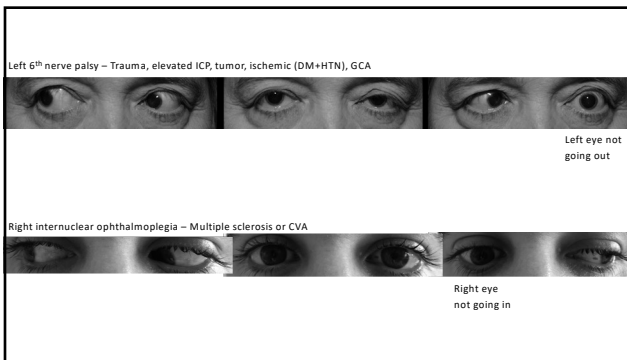
56



57



58



59

Ocular Emergencies

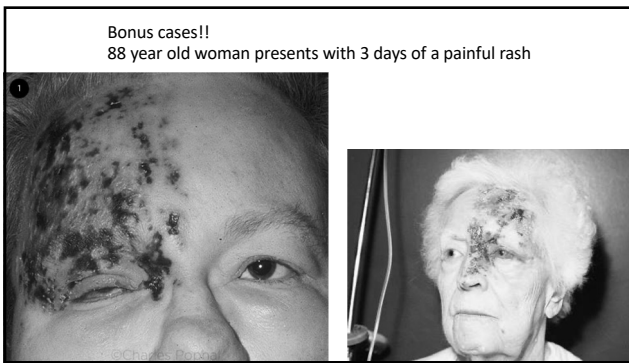1. Acute, *painless* vision loss
2. Acute, *painful* vision loss
3. Acute onset, binocular double vision

Don't forget to think slow

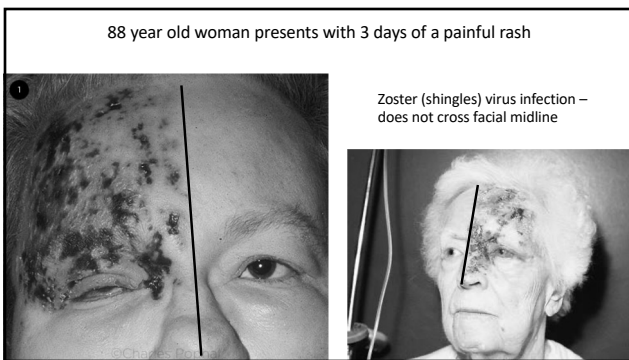60



61



62



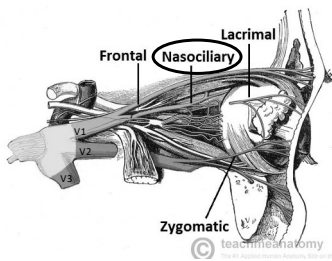
63

Hutchinson's Sign



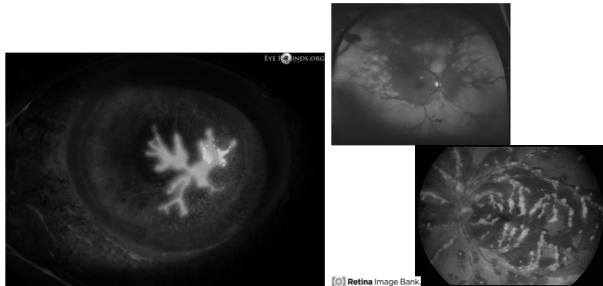
64

Hutchinson's Sign



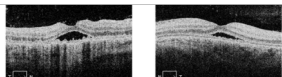
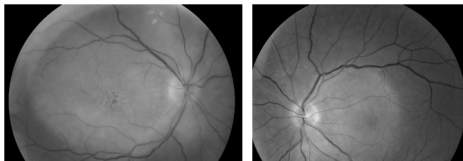
65

Ocular manifestations of VZV and HSV



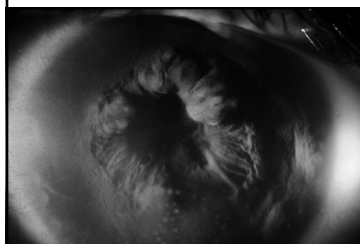
66

42 year old man with ocular discomfort and vision loss in both eyes



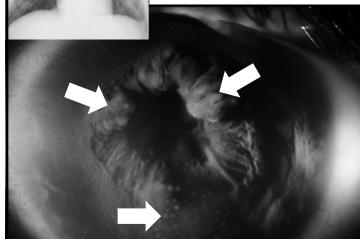
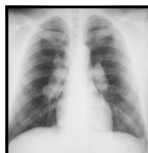67

32 year old man with inflammatory arthritis, and acute onset blurriness, eye pain and redness?



68

32 year old man with inflammatory arthritis, and acute onset blurriness, eye pain and redness?



Sarcoidosis, which is often associated with acute anterior uveitis. External photograph of the eye shows Mutton Fat keratic precipitates and granulomatous iris nodules at the pupillary margin.

69
