

# Scleral Lenses: When Nothing Else Works

Reid Wilson, MD, PhD  
Casey Eye Institute  
March 11<sup>th</sup>, 2022

---

---

---

---

---

---

---

1

## Case 1

- 43 year old male with no significant medical or ocular history presenting for annual vision eye exam
- Uncorrected visual acuity: 20/50 in right eye, 20/40 in left eye
- Manifest refraction:
  - -2.00 + 1.25 x 086
  - -1.75 + 0.75 x 078
  - Add: +1.00
- Best corrected visual acuity 20/20 far, J1 near

---

---

---

---

---

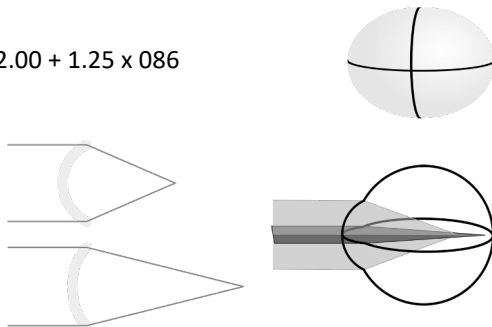
---

---

2

## Regular astigmatism

-2.00 + 1.25 x 086



---

---

---

---

---

---

---

3

### Regular astigmatism

MRx to correct astigmatism

---

---

---

---

---

---

---

---

4

### Case 2

- 43 yo male with history of keratoconus presenting for annual vision exam
- Uncorrected visual acuity 20/70, 20/60
- Manifest refraction:
  - -2.00 + 1.25 x 086
  - -1.75 + 0.75 x 078
  - Add: +1.00
- Visual acuity with manifest refraction: 20/40, 20/30

---

---

---

---

---

---

---

---

5

### Keratoconus

Normal Cornea      Keratoconus

Aqueous Humour      Iris      Lens

Cornea

---

---

---

---

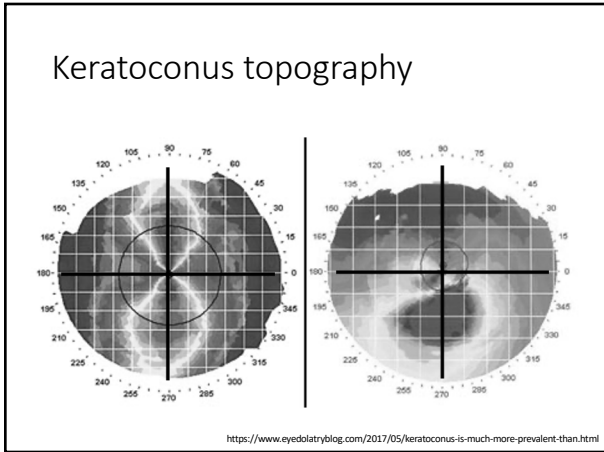
---

---

---

---

6



7

---

---

---

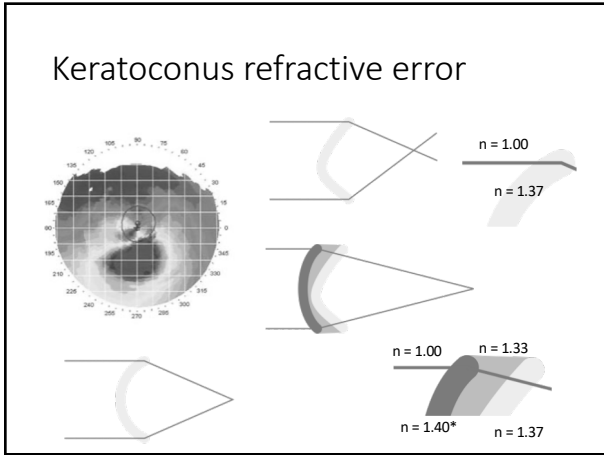
---

---

---

---

---



8

---

---

---

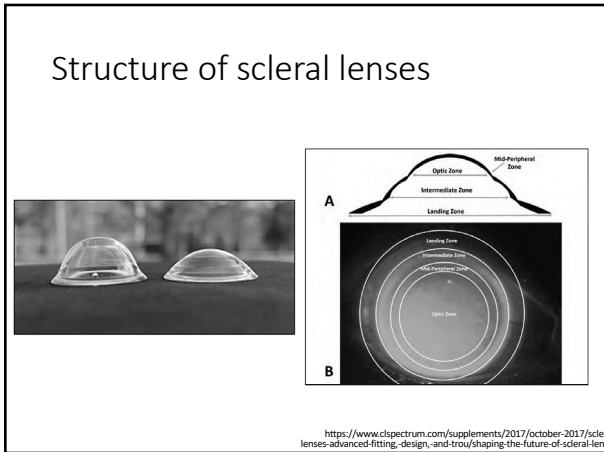
---

---

---

---

---



9

---

---

---

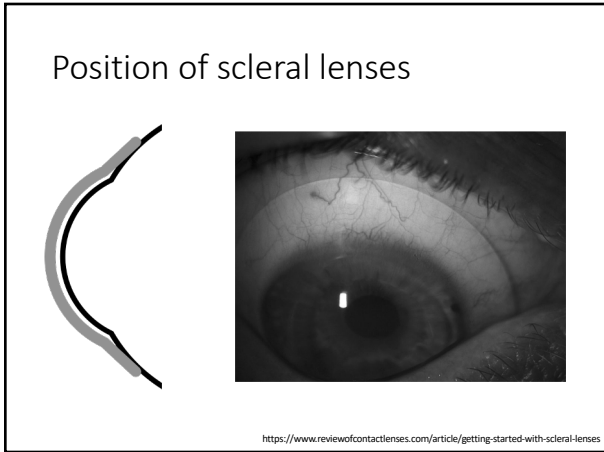
---

---

---

---

---




---

---

---

---

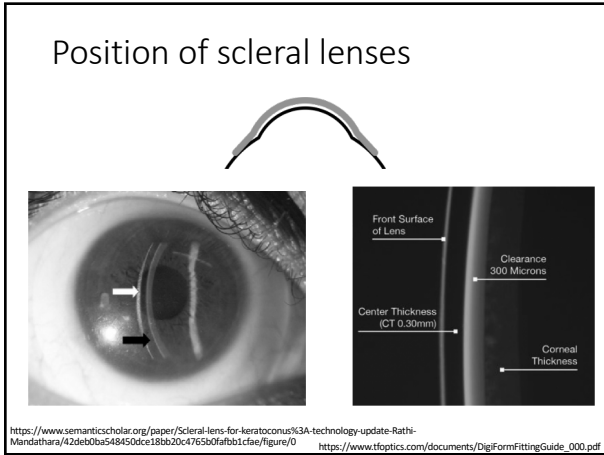
---

---

---

---

10




---

---

---

---

---

---

---

---

11

Case 3

- 43 yo female with large paracentral corneal scar from remote history of perforating corneal injury who presents for annual vision exam
- Uncorrected visual acuity 20/70, 20/20
- Manifest refraction:
  - -2.00 + 1.25 x 086
  - -0.25 + 0.25 x 004
  - Add: +1.00
- Visual acuity with manifest refraction: 20/40, 20/20

---

---

---

---

---

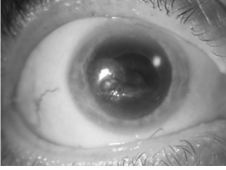
---

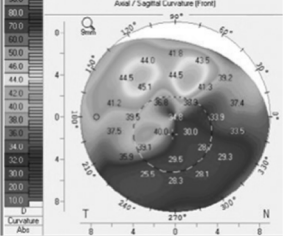
---

---

12

## Corneal Scarring





<https://www.reviewofcontactlenses.com/article/no-pain-no-gain>

---

---

---

---

---

---

---

---

---

---

13

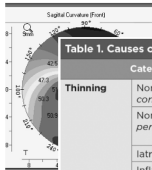



Table 1. Causes of Corneal Irregular Astigmatism		
Category	Causes/examples	
<b>Thinning</b>	Non-inflammatory; corneal	Keratoconus, posterior keratoconus
	Non-inflammatory; peripheral	Pellucid marginal degeneration, Terrien's marginal degeneration, keratoglobus, dellen
	Iatrogenic	LASIK, PRK, pterygium removal
	Inflammatory; peripheral	Rheumatic thinning/ulcer, Mooren's ulcer, shield ulcer
<b>Non-thinning</b>	Infectious	Microbial keratitis, herpetic ulcer
	Deposits	Band keratopathy, vortex keratopathy
	Degenerative	Corneal edema
	Dystrophy; epithelial	Basement membrane dystrophy
	Dystrophy; stromal	Lattice dystrophy
	Mechanical	Rigid gas permeable lens warpage
	Mechanical; adnexal	Ptosis
	Iatrogenic; corneal incisions	Cataract incision wound, radial keratotomy
	Iatrogenic; other surgical procedures	Trabeculectomy, glaucoma shunt procedure, pterygium removal
	Traumatic	Penetrating injury, foreign body
Neoplastic; corneal	Pterygium	
Neoplastic; adnexal	Chalazion, tumor	



<https://www.ajco.com/cn>  
<https://www.djo.eg.net/>  
<https://eyewiki.aao.org/cases/180-Saltzman-Nodular-Corneal-Degeneration.htm>  
<https://www.sao.org/image/causes-of-irregular-astigmatism>  
 Table - <https://www.reviewofcontactlenses.com/article/pathologic-causes-of-irregular-astigmatism>

---

---

---

---

---

---

---

---


---

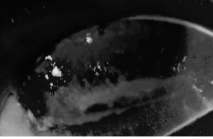
---

14

## Case 4

- 60 yo male with history of Bell's palsy who presents with significant eye pain, redness, and foreign body sensation





<https://webeye.ophth.uiowa.edu/eyeforum/cases/215-facial-nerve.htm> - image  
[https://eyewiki.aao.org/w/images/1/4/41/Fluorescein\\_EK.jpg](https://eyewiki.aao.org/w/images/1/4/41/Fluorescein_EK.jpg) - fluoro

---

---

---

---

---

---

---

---


---

---

15

### Exposure keratopathy

- Scleral lenses provide barrier
- Protect epithelium while it is healing
- Promote hydration




---

---

---

---

---

---

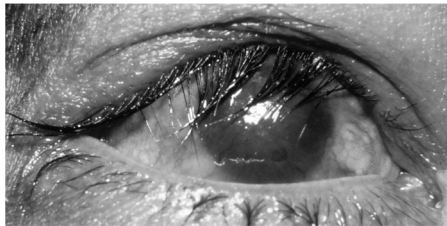---

---

16

### Case 5

- 70 yo female who presents with foreign body sensation, eye pain, blurry vision



<https://opto.ca/health-library/trichiasis> – trichiasis image

---

---

---

---

---

---

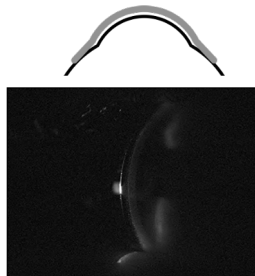
---

---

17

### Complications of scleral lenses

- Decreased oxygen permeability to cornea
  - Fuch's dystrophy is a contraindication
- Corneal abrasions with insertion / removal
- Discomfort with extended wear
- **Mid-day fogging**
- Chemical injury from cleaning solution
- Cost



<https://www.cispectrum.com/supplements/2017/october-2017/scleral-lenses-advanced-fitting-design-and-trou/scleral-contact-lens-complications-midday-fogging>

---

---

---

---

---

---

---

---

18

## Summary

- Two broad categories of indications for scleral lens use:
  - Irregular astigmatism: replaces abnormal ocular surface
  - Protection of ocular surface: physical barrier
- Most common complication of scleral lenses include mid-day fogging.
- Other complications include corneal abrasions, chemical injuries. Infections are rare.
- Proper fit is important to safe scleral lens use

---

---

---

---

---

---

---

---