

Cranial Nerves/ Pupils

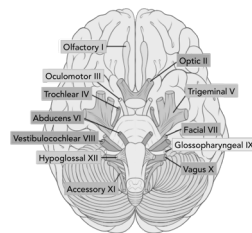


Noah Simon, MD

1

Outline

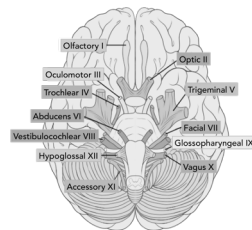
- Cranial Nerves Overview
- Extraocular muscles
- Motility Exam
- Pupils and Innervation
- Pupil Exam
- Nerve Palsies
- Practice Cases



2

Cranial Nerves Overview

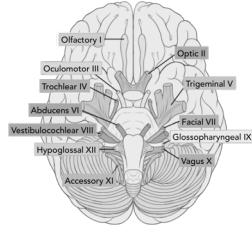
- 1) General functions of cranial nerves
 - a) Special sensory
 - i) Sight, smell, hearing
 - b) Motor
 - i) Muscles
 - c) Sensory
 - i) Touch
 - d) Mixed (combination)



3

Cranial Nerves Overview (simplified)

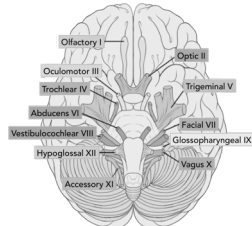
- 1) Olfactory - Smell
- 2) Optic - Sight (from retina)
- 3) Oculomotor - Eyelid and eyeball
- 4) Trochlear - One eye muscle
- 5) Trigeminal - Sensation to face and muscles of mastication
- 6) Abducens - One eye muscle
- 7) Facial - Muscles of the face
- 8) Vestibulocochlear - inner ear
- 9) Glossopharyngeal - several functions including taste
- 10) Vagus - output to viscera (intestines)
- 11) Accessory - Neck and shoulders
- 12) Hypoglossal - Tongue



4

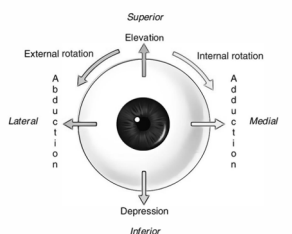
Cranial Nerves Overview (simplified)

- 1) Olfactory - Smell
- 2) Optic - Sight (from retina)
- 3) Oculomotor - Eyelid and eyeball
- 4) Trochlear - One eye muscle
- 5) Trigeminal - Sensation to face and muscles of mastication
- 6) Abducens - One eye muscle
- 7) Facial - Muscles of the face
- 8) Vestibulocochlear - inner ear
- 9) Glossopharyngeal - several functions including taste
- 10) Vagus - output to viscera (intestines)
- 11) Accessory - Neck and shoulders
- 12) Hypoglossal - Tongue



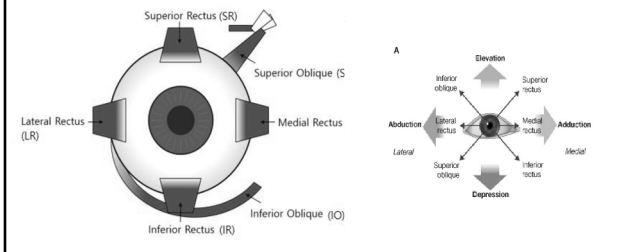
5

Extraocular muscles



6

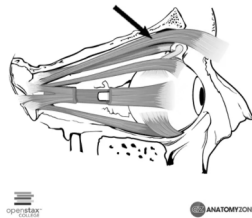
Extraocular muscles



7

Extraocular muscles

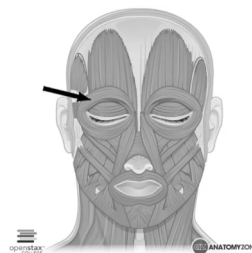- Levator palpebrae superioris (aka "the levator")
- Responsible for voluntary eyelid opening
- Yoked with the other EOM muscles



8

Extraocular muscles

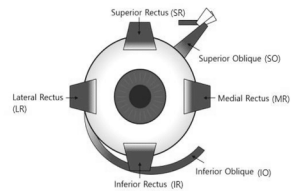
- Orbicularis Oculi
- Part of one of many muscles of facial expression
- Involved in voluntary closing of the eye and blinking



9

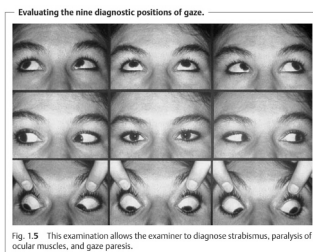
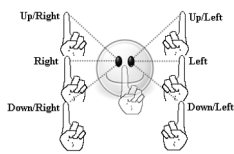
Extraocular muscles - Innervation

- 1) CN 3: Oculomotor nerve
 - a) All EOM except SO and LR
 - b) Levator = opening the eye
- 2) CN 4: Trochlear
 - a) Superior oblique (SO)
- 3) CN 6: Abducens
 - a) Lateral rectus (LR)
 - b) "Abducts" the eye
- 4) CN 7: Facial Nerve
 - a) Muscles of facial expression
 - b) Including orbicularis = closing the eye



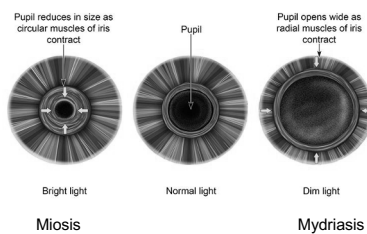
10

Extraocular muscles - Examination



11

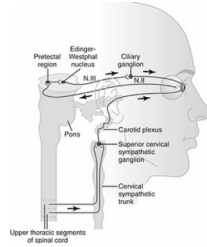
Pupils - Muscles



12

Pupils - Innervation

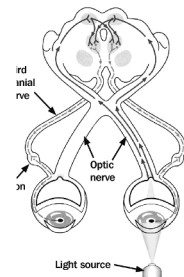
- 1) Constriction
 - a) Innervated by **parasympathetics**
 - b) Exits at brainstem
 - c) ***Travels with CN III (oculomotor)***
- 2) Dilation
 - a) Innervated by **sympathetics**
 - b) Exits at spinal cord
 - c) Travels within the thorax and then with the carotid artery



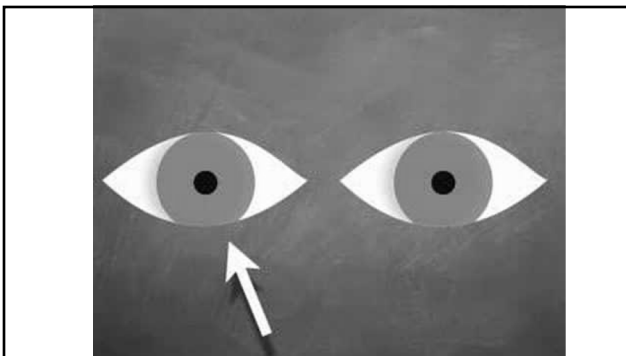
13

Pupils - Light reflex pathway

- 1) Afferent pathway
 - a) Light into eye -> retina -> optic nerve to brainstem
- 2) Efferent pathway
 - a) Brainstem -> pupil via CN III (as discussed in last slide)
 - b) This signal is sent **bilaterally**



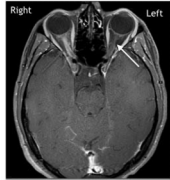14



15

"Nerve" Palsies - Optic neuritis (cranial nerve 2)

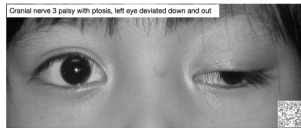
- 1) Typical optic neuritis:
- 2) Etiology: autoimmune inflammation in the optic nerve
- 3) Most commonly seen in young females
- 4) Signs/symptoms
 - a) Unilateral vision loss
 - b) **RAPD**
 - c) Pain with eye movement
- 5) Associated with multiple sclerosis



16

Nerve Palsies - CN 3

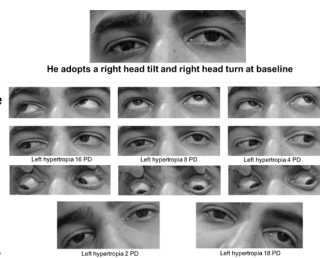
- 1) Reminder:
 - a) CN 3 innervates 4/6 of the extraocular muscles + levator + parasympathetics to pupil
 - b) Affected side:
 - i) Eye is **down and out**
 - ii) Ptosis
 - iii) +/- blown pupil (mydriasis)***
 - c) Most common acquired etiologies: ischemic stroke, aneurysm



17

Nerve Palsies - CN 4

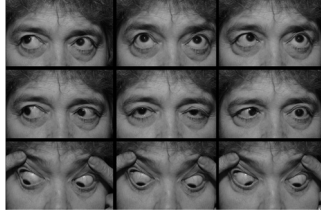
- 1) Reminder:
 - a) CN 4 innervates solely the superior oblique
 - i) Intorsion, depression, some abduction
 - b) Affected side:
 - i) Eye is **hypertropic** (elevated)
 - c) Example: Left CN 4 palsy
 - i) Left hypertropia (S)
 - ii) Worse on right gaze (O)
 - iii) Worse left head tilt (S)
 - d) Most common acquired etiology: trauma



18

Nerve Palsies - CN 6

- 1) Reminder:
 - a) CN 4 innervates solely the lateral rectus
 - i) Pure abduction
 - b) Affected side:
 - i) Lateral gaze deficiency
 - c) Most common acquired etiology: Elevated intracranial pressure



19

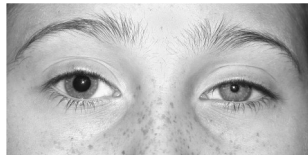Summary: CN 3, 4, 6

- 1) CN 3: Eye is "down and out" with droopy lid, consider aneurysm if pupil is blown
- 2) CN 4: Patient tilts head away from lesion, consider trauma or congenital
- 3) CN 6: Patient appears to be "cross-eyed," consider increased intracranial pressure

20

"Nerve" Palsies - Horner's syndrome

- 1) Loss of sympathetic innervation to one side of the face
- 2) Reminder:
 - a) Sympathetics dilate the pupil, elevate the lid (Muller's muscle), increase sweating
 - b) Patient will present with **ptosis, miosis, +/- anhidrosis**
 - c) Numerous etiologies



21

Case 1:

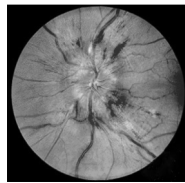
- 1) 29 year old woman with a history of obesity presents with several months of headaches, nausea/vomiting, and more recent double vision. What cranial nerve do you suspect? What might you see on her dilated fundus exam?



22

Case 1:

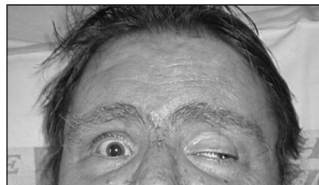
- 1) Increased intracranial pressure
- 2) Associated with right CN 6 palsy
- 3) Optic disc edema (shown on right)
- 4) Given history, would suspect IIH (idiopathic cranial hypertension) but this is a diagnosis of exclusion



23

Case 2:

- 1) A 60 year old diabetic male presents complaining of diplopia. You see this on exam. Upon lifting the left lid, you notice the left pupil is significantly larger than the right. What is your diagnosis? What do you suspect is the etiology?



24

Case 2:

- 1) CN 3 palsy
 - a) Eye down and out
 - b) Ptosis
- 2) Etiology likely compressive lesion (aneurysm)
 - a) Mydriasis
- 3) Urgent brain imaging

