SMILE: The New Kid on the Block

Carlos Torres-Quinones, MD PGY2
Casey Eye Institute - OHSU

1

Corneal Refractive Surgery

- Goal: to render the patient less reliant on refractive aids (glasses and CL)
- Main effect: alter the shape of the cornea in a way that impacts its power
- How do we alter the corneal shape?
  - Mechanisms:
    - Incision (cut)
    - Laser (ablate)
    - Other (implants, heat, cross linking of corneal stroma, etc)

2

Corneal Refractive Surgery

- Goal: to render the patient less reliant on refractive aids (glasses and CL)
- Main effect: alter the shape of the cornea in a way that impacts its power
- How do we alter the corneal shape?
  - Mechanisms:
    - Incision (cut)
    - **Laser (ablate)**
    - Other (implants, heat, cross linking of corneal stroma, etc)

3



Keratoablative Laser Refractive Surgery

- Cornea reshaped to offset the effect of the error lens.

4

What is the error of the corneal lens?

- Is the patient myopic or hyperopic?
- Myopic eye:

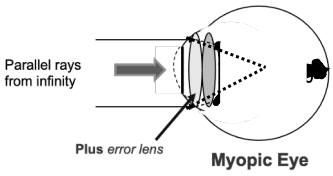

5

What is the error of the corneal lens?

- Is the patient myopic or hyperopic?
- Myopic eye:

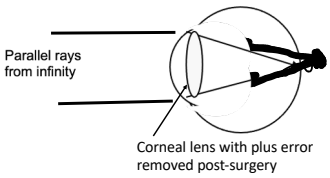

In **myopic keratoablative surgery**, the ***central*** cornea is flattened to **reduce** its converging power

6

What is the error of the corneal lens?

- Is the patient myopic or hyperopic?
- Hyperopic eye:

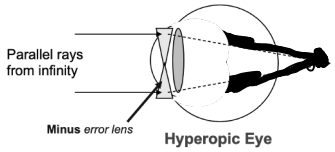

7

What is the error of the corneal lens?

- Is the patient myopic or hyperopic?
- Hyperopic eye:

In hyperopic **keratoablative surgery**, the ***peripheral*** cornea is flattened to **increase** its converging power

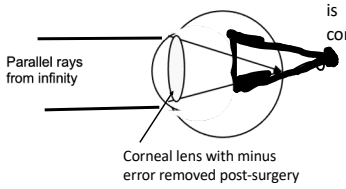

8

Keratoablative Laser Refractive Surgery

- Alter the shape of cornea by the form of ablation, i.e. by annihilation of stromal corneal tissue
  - One laser-based keratorefractive procedure does *not* involve tissue annihilation, rather, in it a section of corneal stroma is carved, then removed *en bloc*

9

5 Types:

- PhotoRefractive Keratectomy – PRK
- LASer In-situ Keratomileusis – LASIK
- LASer SubEpithelial Keratomileusis – LASEK
- Epipolis LASer In-situ Keratomileusis – Epi-LASIK
- SMall-Incision Lenticule Extraction - SMILE

10

Laser based annihilation

- PhotoRefractive Keratectomy – PRK
- LASer In-situ Keratomileusis – LASIK
- LASer SubEpithelial Keratomileusis – LASEK
- Epipolis LASer In-situ Keratomileusis – Epi-LASIK
- SMall-Incision Lenticule Extraction - SMILE

11

PhotoRefractive Keratectomy – PRK

- Epithelium is removed via scraping, chemical destruction, brushing, etc. The epithelium is gone!
- After epithelium removed, excimer laser is used to remove the desired corneal tissue (either centrally or peripherally).
- Advantages: precise removal of tissue
- Most common complication: post-op pain.
- Most feared complication: corneal haze.

12

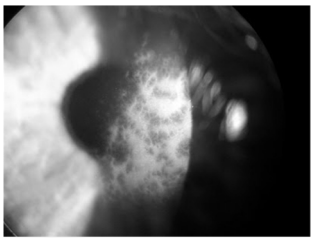

Post-PRK haze

13

LASer In-situ Keratomileusis - LASIK

- Epithelium is cut through with a laser (femtosecond) or blade, and a hinged flap is created.
- The epithelium hinged flap is folded out of the way.
- The corneal stromal bed is ablated with the excimer laser.
- The flap is repositioned.
- Advantages: faster healing, less pain, less risk of haze
- Complications: flap complications, diffuse lamellar keratitis, dry eye

14

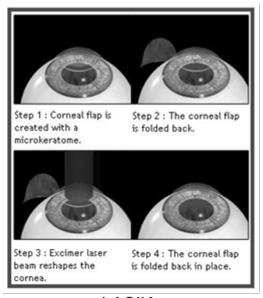

LASIK

15

LASer SubEpithelial Keratomileusis – LASEK

- Epithelium is chemically devitalized and loosened by bathing it in alcohol.
- Loosened epithelium is then folded back, and the ablation is performed.
- The epithelium is smoothed back into place and covered with a bandage CL.
- Advantages: less risk of haze than PRK
- Disadvantages: slower visual recovery than with PRK
- Complications: same as PRK

16

LASEK

17

Epipolis LASer In-situ Keratomileusis – Epi-LASIK

- Epipolis: Greek for "superficial"
- Blunt keratome slides under the epithelium and separates it.
- Epithelium is folded back.
- Cornea tissue is ablated.
- Epithelium is folded back to its place.
- Advantages: less painful than LASEK and PRK

18

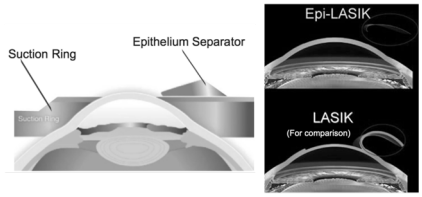

Epi-LASIK

19

SMall-Incision Lenticule Extraction - SMILE

- Femtosecond laser is used to carve a segment (called a *lenticule*) of very specific shape within the stroma without disturbing the overlying or underlying corneal tissue.
- The lenticule is then removed *en bloc* by being extracted through a very small incision (also created by the laser) to reach the lenticule.
- The resulting loss of tissue reshapes the central corneal surface in a way that produces a desired change in its refractive power.

20

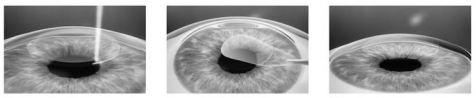

Creation of lenticule and small access (< 4 mm) *Removal of the lenticule* *Refractive error is corrected*

SMILE

21

SMall-Incision Lenticule Extraction - SMILE

Highlights
• An alternative to surface ablation or LASIK refractive surgery. • Currently approved to treat myopia and astigmatism only. • Clinical outcomes of SMILE are comparable to those of PRK or LASIK at 6 months.

Learning objectives:
• Indications and Contraindiations of SMILE • Advantages of SMILE • Disadvantages of SMILE • Complications of SMILE

22

Indications of SMILE

- Myopia from –1.00 D to –10.00 D
- +/- Astigmatism from –0.75 D to –3.00 D
- Patient age 22 or older
- Stable manifest refraction over the past year

23

Relative Contraindications of SMILE

- Insufficient corneal tissue for the amount of correction needed
- Abnormal findings of topography or tomography
- Irregular astigmatism
- Severe or untreated dry eye
- Active infection or inflammation
- Active or prior herpetic or neurotrophic keratitis
- Autoimmune or connective tissue disease
- Uncontrolled glaucoma or diabetes
- Pregnancy or lactation

24

Advantages of SMILE

- No flap is created.
  - More stable cornea
  - Less disruption of anterior corneal innervation (reduced dry eye symptoms)
- Environmental factors have less impact on refractive outcome.

25

Disadvantages of SMILE

- Not available for hyperopic correction
- Limited astigmatic correction
- Slower visual recovery
- Longer procedure time

26

Complications of SMILE

Perioperative complications:	Post-operative complications:
• Epithelial abrasions (6%) • Difficult lenticule extraction (1.9%) • Small corneal tear at the incision (1.8%)	• Trace haze (8%) • Epithelial dryness on post-op day 1 (5%) • Minor interface infiltrates (0.3%) • Irregular astigmatism (1% of eyes) • Diffuse lamellar keratitis • Post-operative ectasia

27

Summary

- Reviewed the principles of keratorefractive surgery.
- Summarized the main differences between the laser-based procedures.
- Discussed in further detail SMILE:
  - Who is a candidate for SMILE?
  - Pros and cons of SMILE
  - Common complications of SMILE

28



Thank You!
Any
Questions?

29