

Ocular Motility Disturbances

Claire Mueller, MD
PGY-3

1

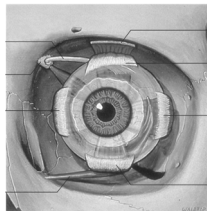
Learning Objectives

1. Accurately test each extraocular muscle using the motility exam.
2. Identify cranial nerve palsies based on the motility exam.
3. Identify the "do not miss" causes of motility disorders.

2

Extraocular Muscles

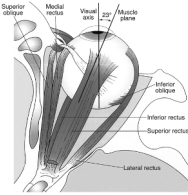
- 4 rectus muscles and 2 oblique muscles
- Origins:
 - Rectus muscles (and levator): Annulus of Zinn
 - Inferior oblique: posterior lacrimal fossa
 - Superior oblique: lesser wing of sphenoid, posterior to annulus of Zinn
 - Effective origin is trochlea
- Insertions:
 - Rectus muscles insert on the anterior sclera
 - Spiral of Tillaux
 - Oblique muscles insert posteriorly



3

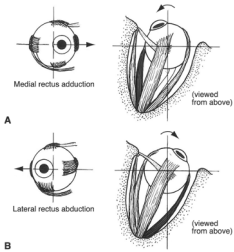
Extraocular Muscles - Innervation

- CN3 - Oculomotor
 - Superior, inferior and medial rectus muscles
 - Inferior oblique and levator palpebrae superioris
 - Pupillary sphincter (parasympathetic)
- CN4 - Trochlear
 - Superior oblique
- CN6 - Abducens
 - Lateral rectus

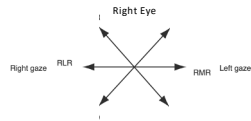


4

Right medial and lateral rectus muscles

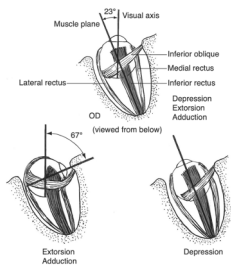


Muscle	Primary	Secondary	Tertiary
Medial rectus	Adduction		
Lateral rectus	Abduction		
Inferior rectus			
Superior rectus			
Inferior oblique			
Superior oblique			

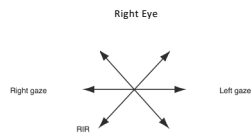


5

Right inferior rectus



Muscle	Primary	Secondary	Tertiary
Medial rectus			
Lateral rectus			
Inferior rectus	Depression	Extorsion	Adduction
Superior rectus			
Inferior oblique			
Superior oblique			



6

Right superior rectus

Muscle	Primary	Secondary	Tertiary
Medial rectus			
Lateral rectus			
Inferior rectus			
Superior rectus	Elevation	Intorsion	Adduction
Inferior oblique			
Superior oblique			

Right Eye

7

Right inferior oblique

Muscle	Primary	Secondary	Tertiary
Medial rectus			
Lateral rectus			
Inferior rectus			
Superior rectus			
Inferior oblique	Extorsion	Elevation	Abduction
Superior oblique			

Right Eye

8

Right superior oblique

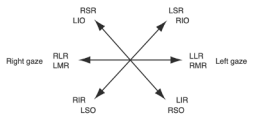
Muscle	Primary	Secondary	Tertiary
Medial rectus			
Lateral rectus			
Inferior rectus			
Superior rectus			
Inferior oblique			
Superior oblique	Intorsion	Depression	Abduction

Right Eye

9

Motility Exam

- Eye movements should be assessed in all positions of gaze
 - Individually (ductions) and together (versions)
- Primary position: when eyes are fixating straight ahead
- Cardinal positions: primary field of action of the EOM
 - The "H" (up and right, right, down and right, down and left, left, up and left)

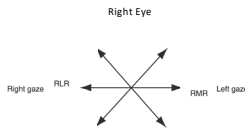


Muscle	Primary	Secondary	Tertiary
Medial rectus	Adduction		
Lateral rectus	Abduction		
Inferior rectus	Depression	Extorsion	Adduction
Superior rectus	Elevation	Intorsion	Adduction
Inferior oblique	Extorsion	Elevation	Abduction
Superior oblique	Intorsion	Depression	Abduction

10

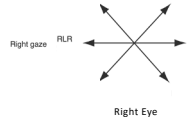
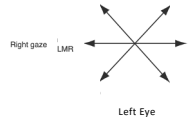
Extraocular Muscles - Laws

- Sherrington's law of reciprocal innervation
 - Reciprocal decrease in innervation to a muscle's antagonist
 - Example: Right eye abduction
 - Innervation to RLR increases and innervation to RMR decreases



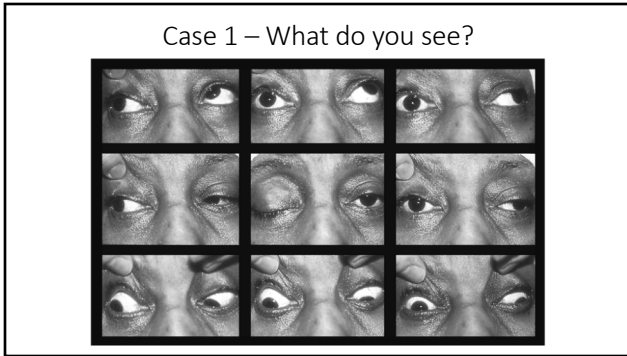
11

Extraocular Muscles - Laws

- Hering's law of motor correspondence
 - Simultaneous and equal increase in innervation to yoke muscles for that direction
 - Example: Right gaze
 - Equal innervation to the RLR and the LMR
 - Amount of innervation is determined by the fixating eye
 - Primary deviation: when the sound eye is fixating
 - Secondary deviation: when the affected eye is fixating

12



13

Case 1 – CN III palsy

Muscle	Primary	Secondary	Tertiary
Medial rectus	Adduction		
Lateral rectus		Extorsion	
Inferior rectus	Depression	Extorsion	Adduction
Superior rectus	Elevation	Intorsion	Adduction
Inferior oblique	Extorsion	Elevation	Abduction
Superior oblique			Abduction

- Motility dysfunction:
 - Superior rectus, inferior rectus, medial rectus, and inferior oblique muscles
 - Eye is "down and out"
- Ptosis:
 - Levator muscle
 - Ipsilateral upper eyelid ptosis
- Partial CN III palsies most common
 - Variable limitation of supra-, infra-, and ad-duction
 - Variable ptosis
- Most important question to ask: is this pupil-involving or not?

14

Case 1 – CN III palsy

With pupillary involvement

- Mid-dilated pupil with poor response to light
- Loss of parasympathetic input
- Pupillomotor fibers are superficial in the medial aspect of nerve
- Aneurysms that arise at the junction of the posterior communicating artery (PCoA) and internal carotid artery (ICA)
- Must rule out compression

Neuro imaging needed!

M. Tsing Sharr, M. (2020). 2020-2021 Basic and Clinical Science Course, Section 5: Neuro-Ophthalmology. American Academy of Ophthalmology.

15

Case 1 – CN III palsy

Microvascular injury (most common)

- Most common for isolated CNIII palsy without pupil involvement*

• Work-up:

- Elevated fasting blood glucose, hemoglobin A1c, serum lipid levels, or blood pressure
- * mild pupil involvement (<1mm anisocoria) in 20%
- Should resolve in 3-6 months

Aneurysmal compression (with pupil involvement)

• Work-up:

- Neuro-imaging: CTA or MRA

Other etiologies:

- Tumor, inflammation (sarcoidosis), vasculitis (GCA), infection (meningitis), infiltration (lymphoma, carcinoma), trauma



16

3rd nerve palsy with aberrant regeneration

- Common after trauma or compression, not with microvascular ischemia

• Primary aberrant regeneration (no history of CN III palsy) is suggestive of a slowly expanding parasellar lesion

- Most commonly a meningioma or carotid aneurysm within the cavernous sinus

- Requires neuroimaging

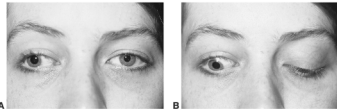
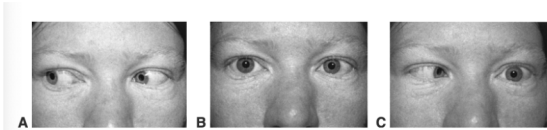


Figure 7-10 Aberrant regeneration of the right CN III. A, In primary gaze, there is mild ptosis, pupillary mydriasis, and exotropia, all on the right. B, With attempted downward gaze, the right eyelid retracts as fibers of the right CN III that innervate the inferior rectus now also innervate the levator muscle. (Courtesy of Rod Forrester, MD.)

17

Case 2 – What do you see?

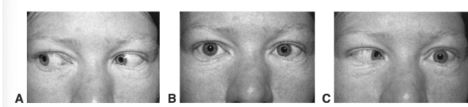


- Abduction deficit of the left eye
- Esodeviation in primary gaze
 - Increases with gaze to the affected side
- What muscle and nerve are involved?

Muscle	Primary	Secondary	Tertiary
Medial rectus	Adduction		
Lateral rectus	Abduction		
Inferior rectus	Depression	Extension	Adduction
Superior rectus	Elevation	Intorsion	Adduction
Inferior oblique	Extorsion	Elevation	Abduction
Superior oblique	Intorsion	Depression	Abduction

18

Case 2 – CN VI palsy



- Ischemia - most common etiology
 - Should improve after 3 months
 - May require imaging or labs to rule out other etiologies if no improvement
- Other etiologies:
 - Elevated intracranial pressure
 - GCA, ocular myasthenia gravis, sarcoidosis, syphilis, trauma
 - Posteriorly draining CC fistula
 - Lesions of cerebellopontine angle (acoustic neuroma or meningioma)
 - Contiguous CNs affected
 - Decreased facial / corneal sensation, facial paralysis, decreased hearing with vestibular signs

19

Something to consider... restriction vs paretic

Paresis:

- Neural signal not reaching muscle

Restriction:

- Something preventing muscle from acting
 - Associated with orbital signs and symptoms: proptosis or enophthalmos
 - History of orbital trauma, eye surgery, or thyroid eye disease (TED)

20

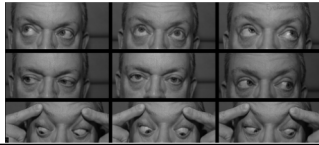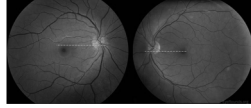
Case 3 – patient with new onset double vision



21

Case 3 – patient with new onset double vision

- Ocular motility often grossly normal
- Right hypertropia in primary
- Worse in left gaze and right head tilt
 - Notice compensatory left head tilt
- 10 degrees of exocyclotorsion
 - Double Maddox Rod
 - Fundus exam / photo



22

Case 3 – CN IV palsy

- Cranial nerve IV (trochlear nerve) innervates the superior oblique
 - Responsible for depression and intorsion
- Binocular vertical or torsional diplopia
- Variable with different gaze directions
 - Worse with contralateral gaze (adduction) and ipsilateral head tilt
 - May adopt a compensatory head tilt
 - Often worse with downgaze
 - Extorsion of the affected eye
- Parks-Bielschowsky three-step test

23

Case 3 – CN IV palsy

- CN IV is vulnerable to closed head trauma
 - Dorsal midbrain crossing – longest coursing CN
 - Can lead to bilateral CN IV
- Bilateral CN IV
 - Large V-pattern esotropia
 - Habitual chin down posture
 - Crossed hypertropia (right eye higher on left gaze, left eye higher on right gaze)
 - Exocyclotorsion >10
- Congenital CN IV
 - Diplopia later in life due to diminishing vertical fusional amplitudes
 - Longstanding head tilt (look for old photos)
 - Large vertical fusional amplitudes >3

24

Resources:

- M. Tariq Bhatti, M. (2020). 2020-2021 Basic and Clinical Science Course, Section 5: Neuro-Ophthalmology. American Academy of Ophthalmology.
- Robert W. Hered, M. (2020). 2020-2021 Basic and Clinical Science Course, Section 6: Pediatric Ophthalmology and Strabismus. American Academy of Ophthalmology.
- Klauer AJ, Kirkpatrick CA, Thurtell MJ. Cranial Nerve IV (Trochlear Nerve) Palsy: 57-year-old male complaining of vertical diplopia after head trauma. EyeRounds.org. posted Nov. 10, 2015; Available from: <http://EyeRounds.org/cases/225-CN-IV-palsy.htm>

25

Q1

Q. What extraocular muscles does the oculomotor nerve supply (CN3)?

1. Superior rectus, inferior rectus, medial rectus, levator
2. Superior rectus, inferior rectus, medial rectus, inferior oblique
3. Superior oblique, inferior oblique, medial rectus, inferior rectus
4. Superior rectus, inferior rectus, medial rectus, lateral rectus

26

Q2

Q. Your patient presents with diplopia that is worse in right gaze. Upon examination, you note that the right eye cannot abduct. What is the correct combination of muscles and nerves responsible for this deficit?

1. Right lateral rectus and left CN3
2. Right lateral rectus and right CN6
3. Left medial rectus and left CN3
4. Right medial rectus and right CN6

27

Q3

Q. The patient you are examining has an eye that has limitations in up-gaze, down-gaze, and adduction. What is the most important next step?

- 1. Dilated fundus exam
- 2. Ask about a history of diabetes or other vascular problems
- 3. Hold on dilation and closely examine the pupils
- 4. Measure vertical fusion amplitudes

28

Q4

Q. Your patient with the "down and out" eye has a mid-dilated and poorly responsive pupil on the affected side. Your patient asks you what they should expect going forward.

- 1. This should all improve in the next 3-6 months
- 2. It is important that you see your primary care doctor for better control of your blood pressure and blood sugars
- 3. We can try to put prism in your glasses to help with the double vision, because this will likely be permanent
- 4. We should order urgent imaging of your brain to rule out an aneurysm or compressive lesion

29

Q5

Q. How can you determine the chronicity of a right CN4 palsy?

- 1. Congenital right CN4 palsy will have smaller vertical amplitudes
- 2. Diplopia worse with a right head tilt and left gaze
- 3. Vertical diplopia with 10 degrees of incyclotorsion measured with double Maddox rod testing
- 4. By looking at old photos and finding a left head tilt

30